

# Management and Outcome of Peyronie's Disease in Nigeria- Initial Experience

AO Takure\*

OM Atalabi\*\*

Division of Urology\*  
Departments of Surgery  
Radiology\*\*  
University of Ibadan and  
University College Hospital  
Ibadan

All Correspondence:  
Dr AO Takure  
Division of Urology,  
Department of Surgery,  
University College Hospital  
Ibadan, Nigeria

E-mail:  
aotakure@yahoo.com

## Abstract

Peyronie's disease is characterized by the formation of fibrous plaques within the tunica albuginea of the corpora cavernosa. It is a frustrating disease to the patient resulting in penile deformity and painful erection and erectile dysfunction. There is mixed response to medical therapy and the numerous surgical options implies no standardized procedure yet. The incidence appears to be increasing but this disease is rarely reported in Nigeria. We present three cases of dorsal and ventral Peyronie's disease treated and followed up for 2years who responded to surgical and medical treatment with satisfactory sexual life and penile erection.

**Key Words:** Peyronie's disease, management, Nigeria

## Introduction

Peyronie's disease is characterized by the presence of fibrous plaques or nodules in the tunica albuginea layer of the penis. It is named after Francois Gigot de la Peyronie, an eighteenth century French surgeon. The disease is commonest between ages 40 and 70<sup>1</sup>. The exact cause is unknown but it is higher in men catheterized per urethra<sup>2</sup>, penile trauma<sup>1,2</sup> and in diabetics<sup>3</sup>. This disease may present as penile pain<sup>2,4</sup>, lump<sup>4</sup>, deformity of the penis on erection<sup>2,4</sup> and impotence<sup>2,5</sup>.

Penile ultrasound is useful in classifying the fibrotic plaques with or without calcifications into three groups from nil to complete<sup>6</sup>. Ultrasonography is important in the presentation of patients for medical treatment and in the monitoring of the response to treatment<sup>5</sup>.

Peyronie's disease can initially be managed by medical non surgical approach<sup>6-8</sup>. In the event of stable disease, marked penile deformity and erectile dysfunction, surgery is the gold standard. Such surgical patient must be informed on the possibility of disease progression and this has necessitated the various surgical options of treatment<sup>9-12</sup>.

Though the incidence is said to be rising in the western world from 0.4%<sup>13</sup> to 3.67% particularly among Caucasians<sup>3</sup>, 5% in Australia<sup>2</sup> and 7.1% in

Asia<sup>14</sup>, this disease is rarely reported in our environment. Hence the case series report of the management and outcome of Peyronie's disease in Nigeria and the need in future to screen our adult male to document the incidence of this frustrating and debilitating disease.

## Case series

1. A 67 year old, known hypertensive, who presented with a 5-month history of pain during intercourse and a lump on the surface of his penis. He had associated emptying and storage lower urinary symptoms of one year duration. No history suggestive of cigarette smoking or alcohol ingestion.

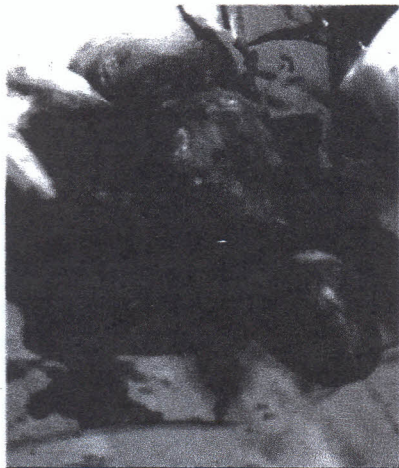Examination then revealed a mass on the dorsum of the penis, around the corona and measured 1cm x 1 cm. In addition a benign enlargement of the prostate gland was confirmed.

Penile ultrasonography showed a hyperechoic area around the penile corona sulcus.

He was placed on alfuzocin (a blocker), non steroidal anti inflammatory drugs and the antihypertensive drug therapy continued. His pain subsided after 5 months, but he presented again on account of penile deformity and disturbed sexual life. He had an excision of the dorsal penile plaque and dermal graft under spinal anaesthesia (see figure 1). During a 2 year and half follow up, there was no palpable penile lump and he continued to enjoy a satisfactory sexual




**Figure 1:** Excision of dorsal and lateral Peyronie's plaque.



2. A 60 year old man, being investigated for lower urinary tract symptoms, presented with two years history of lump of increasing size underneath the penis. The lump was initially painless but later became painful and eventually adversely affected his sexual life.

Examination confirmed two ventral butterfly fibrous plaques at the penoscrotal region that measured 1.5cm x 1.2cm and 1.6cm x 1.5cm. Transverse penile ultrasonography showed bilateral hyperechoic linear bands casting acoustic shadow (figure 2). He was informed of the possible surgical outcome and subsequently had urethral mobilization, excision and fenestrated dermal grafts done. At follow he enjoyed adequate erection but felt a residual lump. Re examination showed disease progression at the edge of the dermal graft and a hypertrophic scar in the lower limb. He was placed on intramuscular monthly triamcinolone 40mg and the plaques gradually reduced in size over a year and half follow up.

**Figure 2:** Transverse/sagittal Penile Ultrasound showing Bilateral Hyperechoic Lesions casting Acoustic Shadows.



3. 50 year old man, married with three children, who presented with weak penile erection of 5 years duration. He noticed dorsal curvature of his penis. There was nocturnal penile tumescence. He neither

smoked cigarette nor drank alcohol.

There was no history suggestive of diabetes mellitus, hypertension or lower urinary symptoms. He was not any routine medications.

Examination revealed a scar in the sternum and extensive dorsal plaques affecting both corporal cavernosae from the penile root to the sub-corona region. Penile ultrasonography showed dorsal hyperechoic lesions involving both corporal cavernosae.

He was placed on intramuscular monthly triamcinolone 40mg x 3 months. At follow up there was complete absence of the dorsal plaque and this was confirmed by ultrasonography.

### Discussion

Peyronie's disease is characterized by the formation of fibrous plaques within the tunica albuginea of the corpora cavernosa<sup>1</sup>.

The prevalence was initially as low as 0.4%<sup>13</sup> but is now reported to be 3.67%<sup>5</sup>, 5%<sup>2</sup>, and 7.1%<sup>14</sup> among male patients. The true prevalence in Nigeria is not known. This informed a search for the presence of asymptomatic penile plaques in middle aged men presenting at our urologic outpatient clinic.

Peyronie's disease is a disease of middle aged men 40-59 years though it has been reported in men from 18 to 80 years old<sup>4</sup>. Our patients were aged 50, 60 and 67 years respectively. Usually these patients may present with penile pain, progressive penile deformity, lump or erectile dysfunction as seen in our patients<sup>2,4,15</sup>.

This disease usually stabilizes between 6 and 12 months as seen in our second case, but it may be earlier as was the case in the first case<sup>16</sup>. Our first patient is a legal practitioner and therefore more conscious about his condition.

All of our patients are married and the possibility of repeated penile trauma during sexual intercourse is quite possible as previously documented<sup>2,14</sup>. These patients neither smoked cigarette nor had urethral catheterization prior to their penile symptoms, although these factors have been implicated in some patients with Peyronie's disease<sup>2,14</sup>. We observed that two patients were being evaluated for lower urinary tract symptoms and wonder whether this could be a coincidence or a risk factor. However, the third patient presented with erectile dysfunction. Our series confirmed all the spectrum of Peyronie's disease manifestation. We believe that a structured prospective study will help in identifying etiological factors. Although the diagnosis of Peyronie's disease can reliably be made on clinical grounds as was the case in our cases, penile ultrasonography showed hyperechoic linear bands with acoustic shadowing in keeping with calcifications along the corporal cavernosae (that is, matured plaques) as in other reported series<sup>17,18</sup>.



Although Lindsay MB, et al<sup>13</sup> found ultrasound to be of limited clinical use, we believe that ultrasonography is cheap, non invasive, readily available and could be an adjunct investigation when in doubt of this disease.

We performed excision of penile plaques and dermal graft in two patients because these patients were more interested in any form of treatment that would remove the penile lump. The patient with dorsal disease had a resolution of his penile deformity and maintained satisfactory intercourse at 2 years follow up. This result is similar to that reported by others after dermal or venous grafts. However the patient with penoscrotal ventral plaque had a rim of fibrosis around his dermal graft at the third month of follow up and this was suggestive of disease progression and this does occur in patients with any form of graft based procedures<sup>7-10</sup>. His lesion improved on monthly intralesional steroid at the end of 12 months follow up. The third patient with erectile dysfunction due to the dorsal plaques had complete resolution of the plaques after 3 months on injectable triamcinolone. Intralesional steroid has been found to give good response but there is atrophy of the tunica albuginea and thinning out of the penile skin<sup>12,13</sup>. Intralesional verapamil<sup>8</sup> has been found to reduce pain, slow down the progression of the Peyronie's disease but this form of injection is not readily available in our country, hence our choice of intra-lesional steroid.

In conclusion, Peyronie's disease is rarely reported in Nigerians though it is common in the Western world and it has easily recognizable clinical and radiological features. It responded to both surgical and medical therapy. A prospective study is needed to establish the prevalence, risk factors, and outcome of treatment of this disease in our environment.

#### Acknowledgement

The entire patients who agreed to this case reports. Dr. D. Irabor, consultant Surgeon, Department of Surgery, University College Hospital for the critical review of the final write up.

Dr. Shaibu DM, Medical Director at Nigerian National Petroleum Cooperation (NNPC) Medical Centre, Benin-city, Nigeria; for the encouragement in writing this article.

#### References

1. Sommer F, Schwarzer U, Wassmer G, Bloch W, Braun M, Klotz T, Engelmann. Epidemiology of Peyronie's disease. *Int J Impot Res* 2002; 14(5): 379-383.
2. Johnson HM, Weerakoon P, Stricker PD. The Incidence, Etiology, and Presentation of Peyronie's Disease in Sydney, Australia. *Sexuality and Disease* 2002; 20(2): 109-116.
3. Arafa M, Eid H, El-Badry A, Ezz-Eldine K, Shamloul R. The prevalence of Peyronie's disease in diabetic patients with erectile dysfunction. *Int J Impot Res* 2007; 19(2): 213-217.
4. Pryor JP, Ralph DJ. Clinical presentations of Peyronie's disease. *Intl J Imp Res* 2002; 14(5): 414-417.
5. Rhoden EL, Teloken C, Ting HY, et al. Prevalence of Peyronie's disease in men over 50-y-old from Southern Brazil. *Intl J Imp Res* 2003; 13(5): 291-293.
6. Anderson R, Wegner HE, Banzer D, Miller K. Ultrasound and soft tissue radiography to monitor local interferon-alfa 2B treatment in Peyronie's disease. *Acta Radiol* 1996; 37(3): 352-356.
7. Akin-Olugbade Y, Mulhali JP. The medical management of Peyronie's disease. *Nat Clin Pract Urol* 2007; 4(2): 95-103.
8. Levine LA, Estrada CR. Intralesional verapamil for the treatment of Peyronie's disease: a review. *Intl J Imp Res* 2002; 14(5): 324-328.
9. Devine CJ, Jr, Horton CE. Surgical treatment of Peyronie's disease with a dermal graft. *J Urol* 1974; 111: 44-49.
10. Goyal NK, Kumar A, Das SK, et al. Experience with plaque excision and dermal graft in the surgical treatment of Peyronie's disease. *Singapore Med J* 2008; 49(10): 805-808.
11. Adeniyi AA, Goorney SR, Pryor JP, et al. The Lue procedure: an analysis of the outcome in Peyronie's disease. *BJU Int* 2002; 89(4): 404-408.
12. Akkus E, Ozkara H, Alici B, et al. Incision and venous patch graft in the surgical treatment of penile curvature in Peyronie's disease. *Eur Urol* 2001; 40(5): 531-537.
13. Lindsay MB, Schain DM, Grambasch P. The incidence of Peyronie's disease in Rochester, Minnesota, 1950 through 1984. *J Urol*. 1991; 146:10071009.
14. La Pera G, Pescatori ES, Calabrese M, Boffini A, Colombo F. SIMONA Study Group. Peyronie's Disease: Prevalence and Association with Cigarette Smoking: A Multicenter Population-Based Study in Men Aged 50-69 Years. *Eur Urol* 2001; 40: 525-530.
15. Gholami SS. Lue T.F. Peyronie's disease. *Urol Clin North Am* 2001; 28(2): 377-390.
16. Jalkut M, Gonzalez-Cadavid N, Rajfer J. Peyronie's Disease: A Review. *Urol* 2003; 5(3): 142-148.
17. Balconi G, Angeli E, Nessi R, et al. Ultrasonographic evaluation of Peyronie's disease. *Urol Radiol* 1988; 10(2): 85-88.
18. Amin Z, Patel U, Friedman EP, Vale JA, Kirby R, Lees WR. Colour Doppler and duplex ultrasound assessment of Peyronie's disease in impotent men. *Bri J Rad* 1993; 66: 398-402.